

Diagnosis of Smallpox

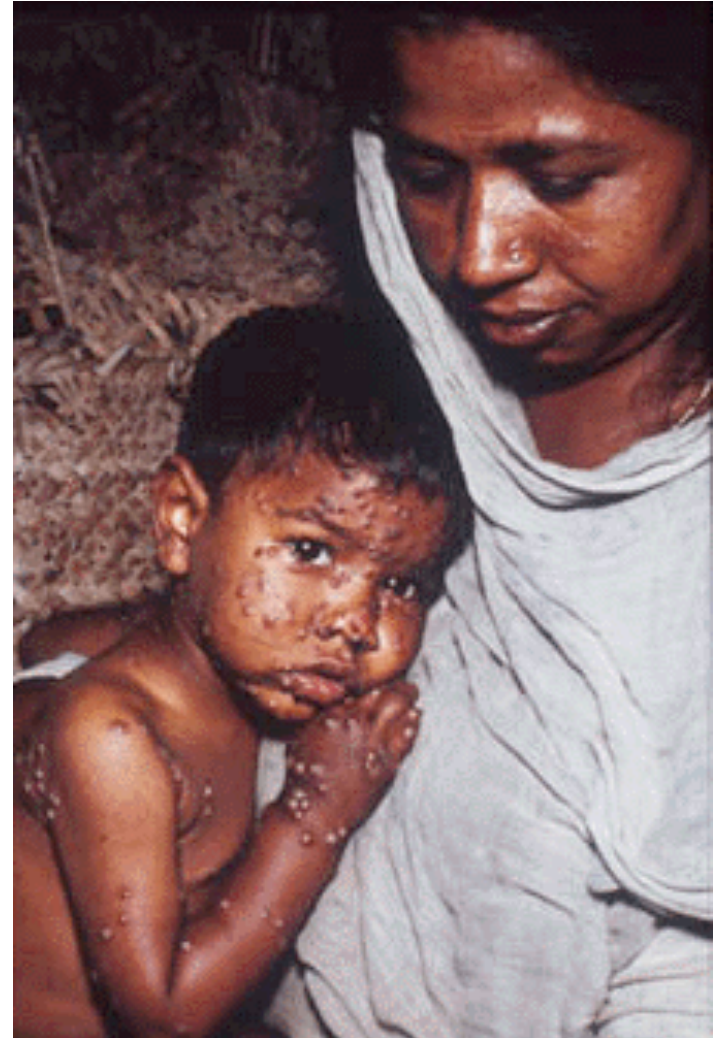Smallpox is a disease that can be easily diagnosed by the average health worker. In this series of slides, typical cases of smallpox are presented. Such cases account for 9 out of 10 patients who are seen. Because smallpox is sometimes confused with chickenpox, pictures of patients with chickenpox are included for comparison. **In the post-eradication era, the detection of a case of smallpox is a public health emergency.**

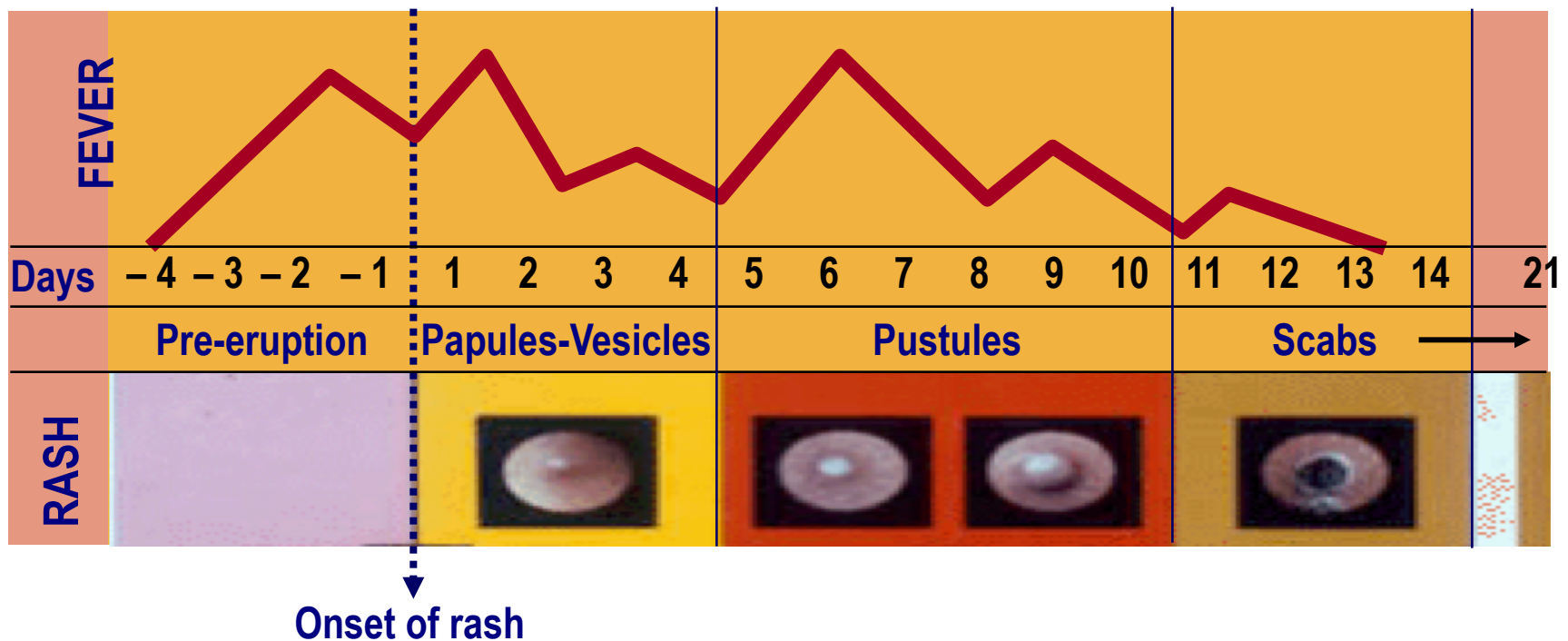
- Notify the health authority immediately.
- Isolate the patient.
- Vaccinate all contacts.



World Health Organization

Smallpox is a disfiguring disease. Three out of ten cases may die. It is caused by variola virus. The disease is spread by secretions from the patient's mouth and nose, and by material from pocks or scabs. It is transmitted directly from one person to the next. Close contact with patients, or their clothing or bedding, is thus required for infection. A patient who has developed the distinctive symptoms of smallpox will have been exposed to the virus about two weeks previously.



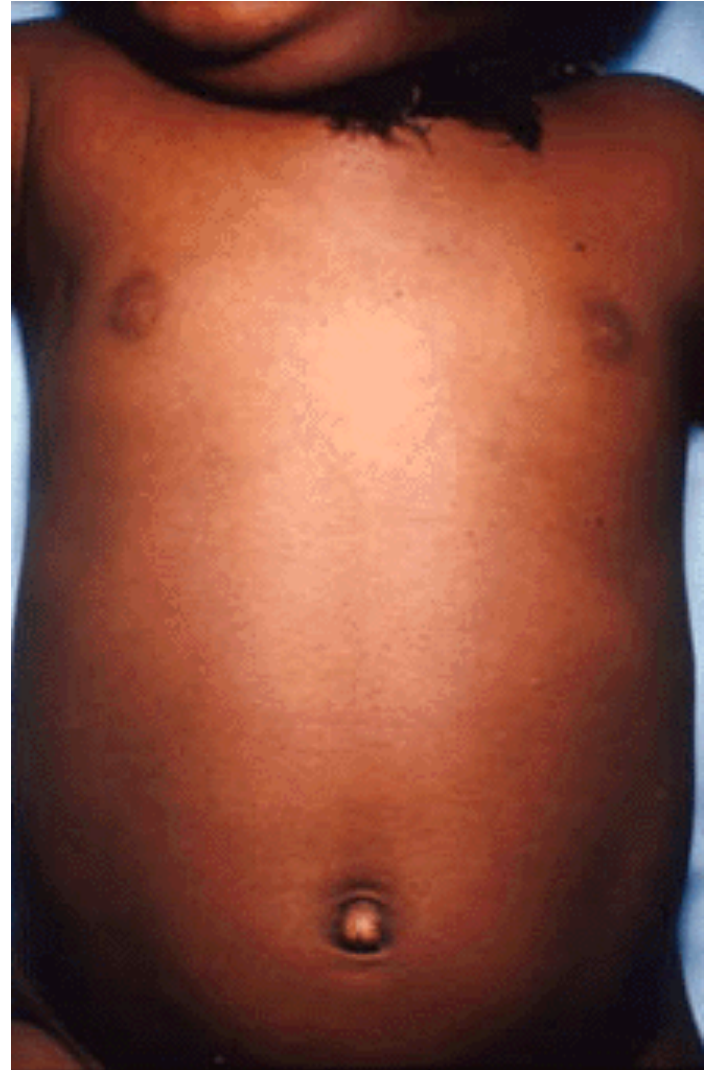

After a person has been infected through exposure to the smallpox virus, a symptom-free period follows. This is called the incubation period. It is normally 12 days in length but may be as short as 7 days or as long as 17 days.

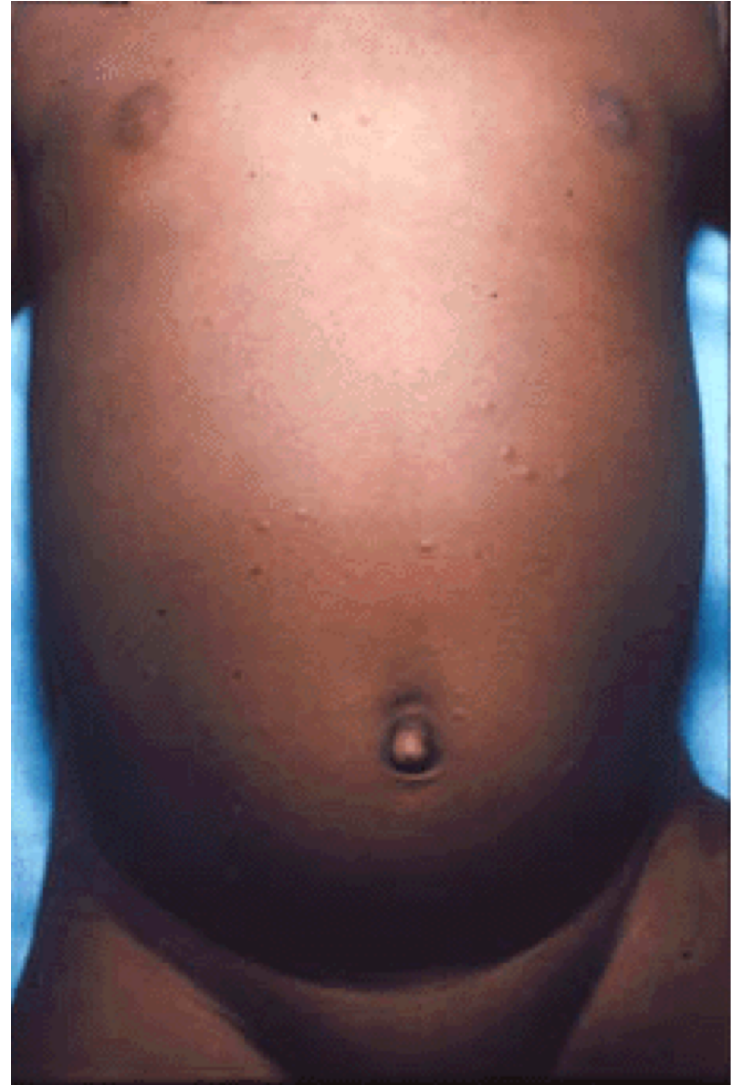The illness begins with fever. The patient feels sick and has symptoms such as headache and severe backache.

A rash appears after 2 to 4 days and progresses through characteristic stages of papules, vesicles, pustules and finally scabs. The scabs fall off at the end of the 3rd or 4th week.

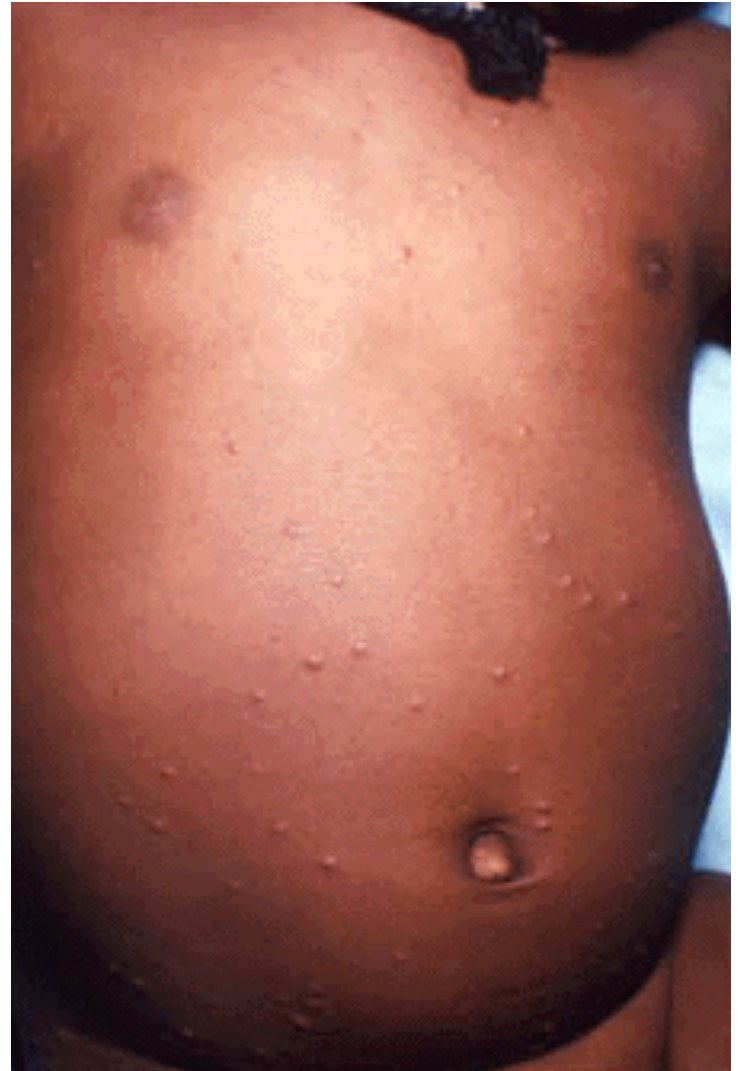The rash appears 2 to 4 days after the patient first becomes ill with fever. On the first day of rash a few raised spots called papules appear. They are usually seen first on the face, and subsequently on the body and extremities. On the right side of this picture, a few small papules may be seen. Unless it is known that the patient has been exposed to the virus or in contact with a smallpox case two weeks before, one may not suspect the diagnosis at this time.



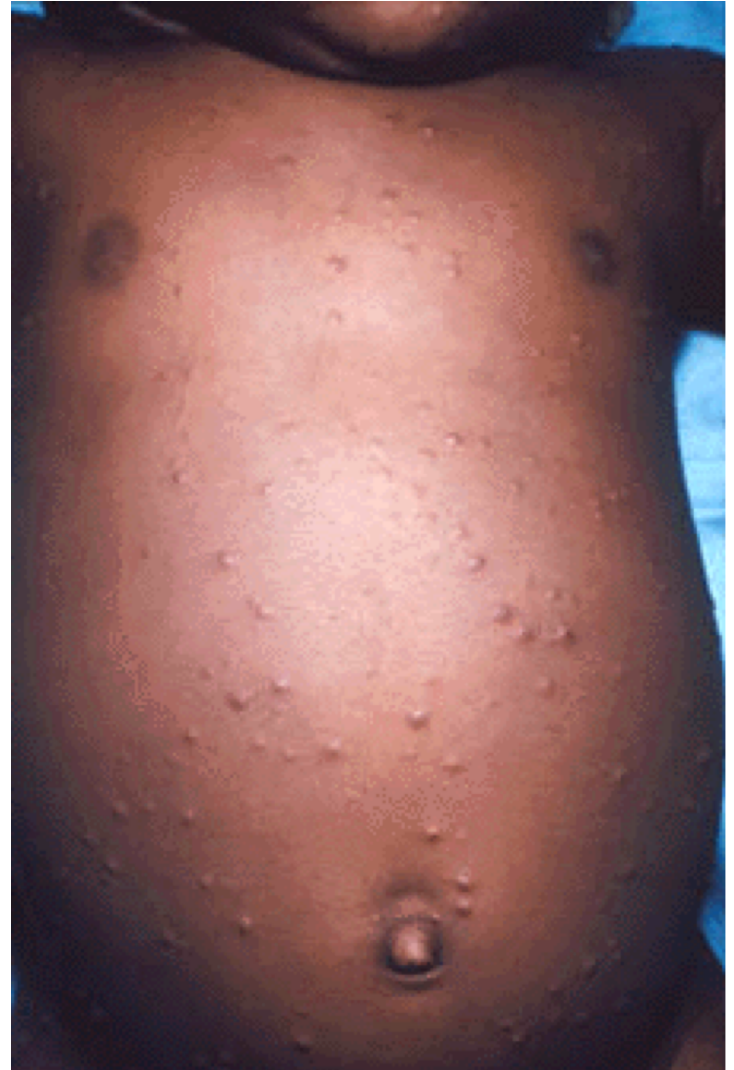**On the second day of rash,
more papules appear.
Although they differ
somewhat in size, note that
they all have a very similar
appearance.**



By day 3, the rash has become more distinct and raised above the skin surface. Fluid is accumulating in the papules to form vesicles.

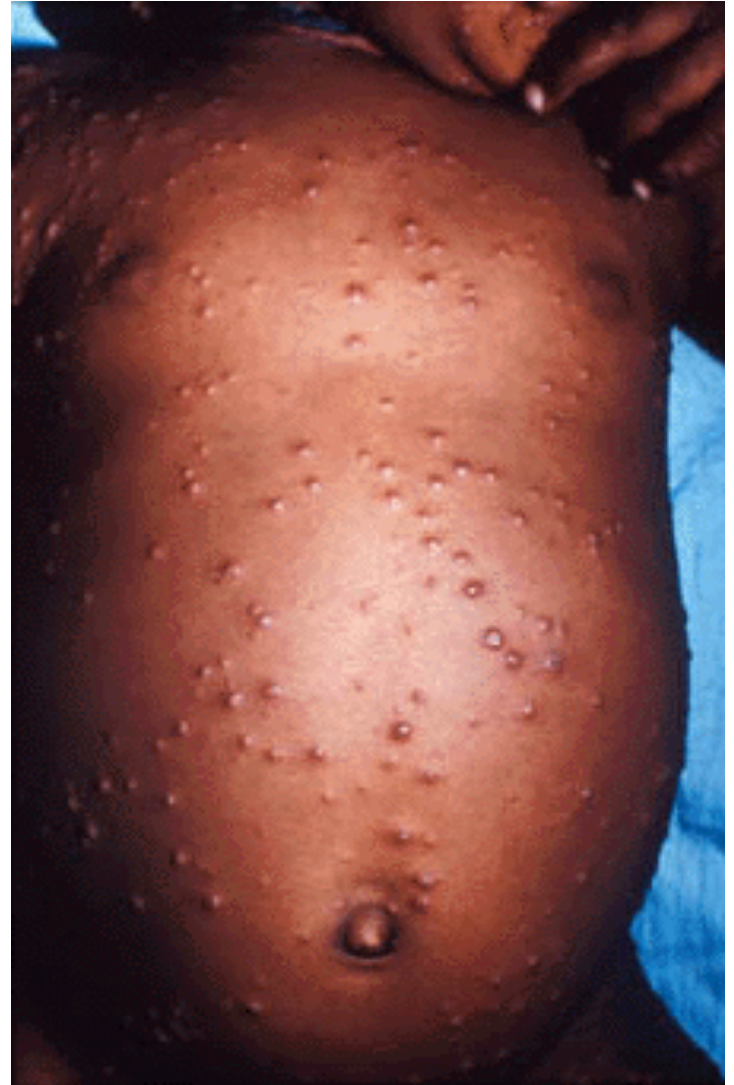

By day 4, the vesicles are more distinct. Although they contain fluid, they feel very firm to the touch. When broken, they do not collapse because the fluid is contained in many small compartments.

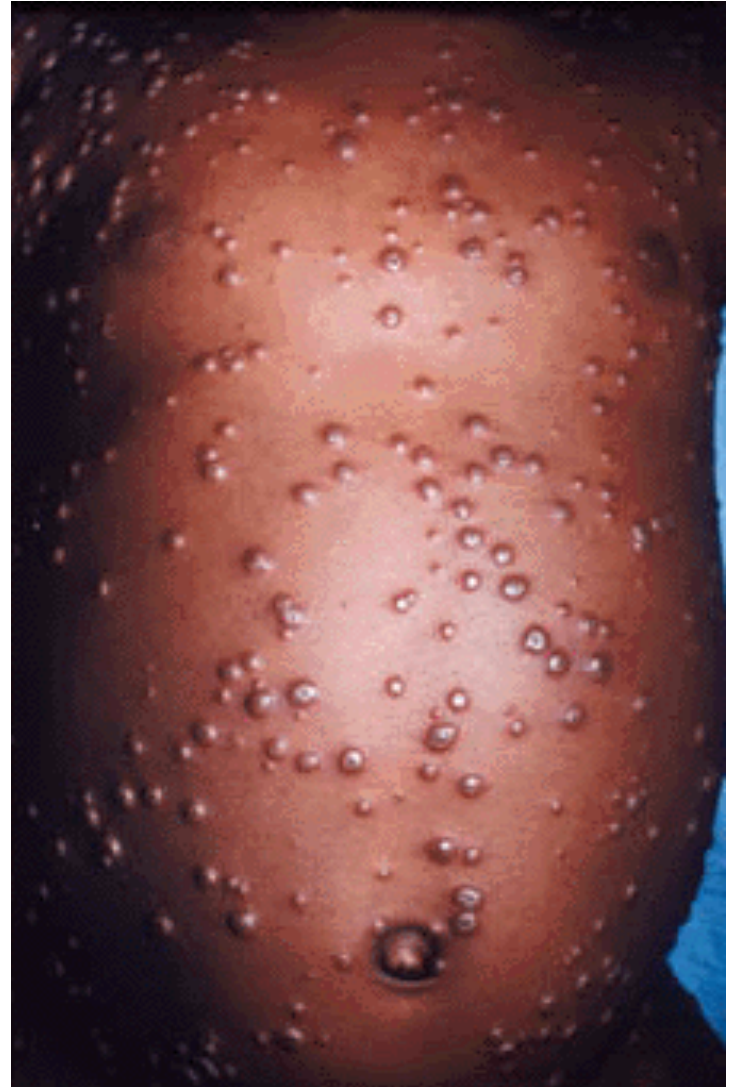

By day 5, the fluid in the vesicles has become cloudy and looks like pus. At this stage, the pocks are called pustules.

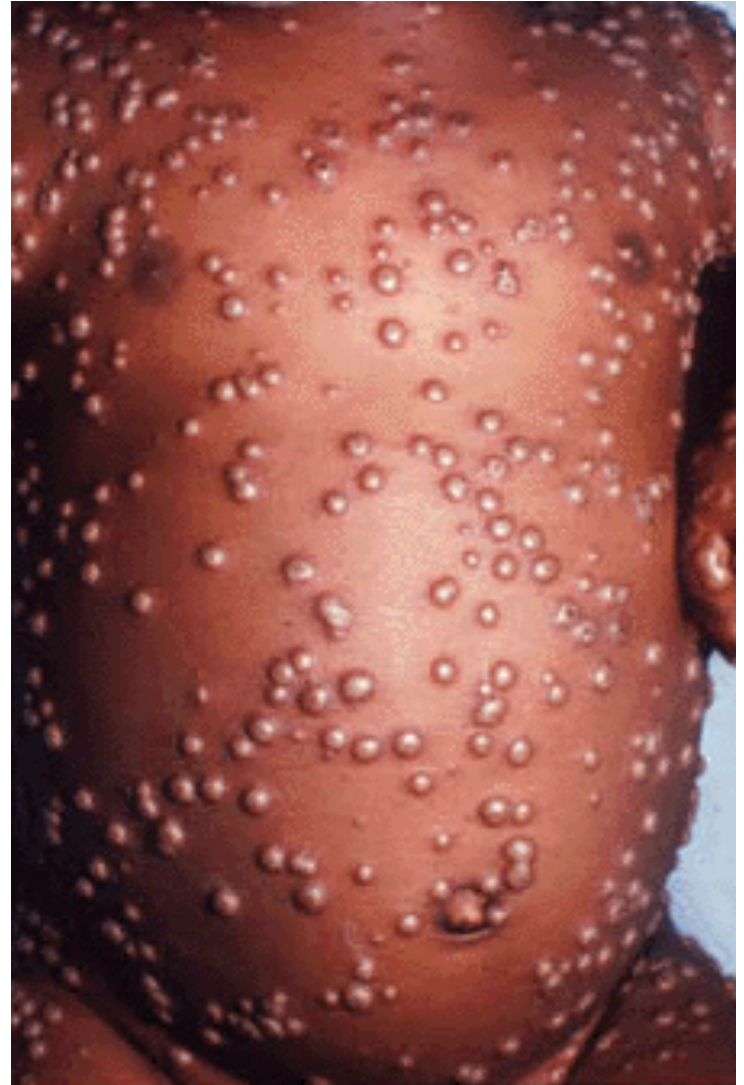
At this time, the fever usually rises and the patient feels more ill than before.



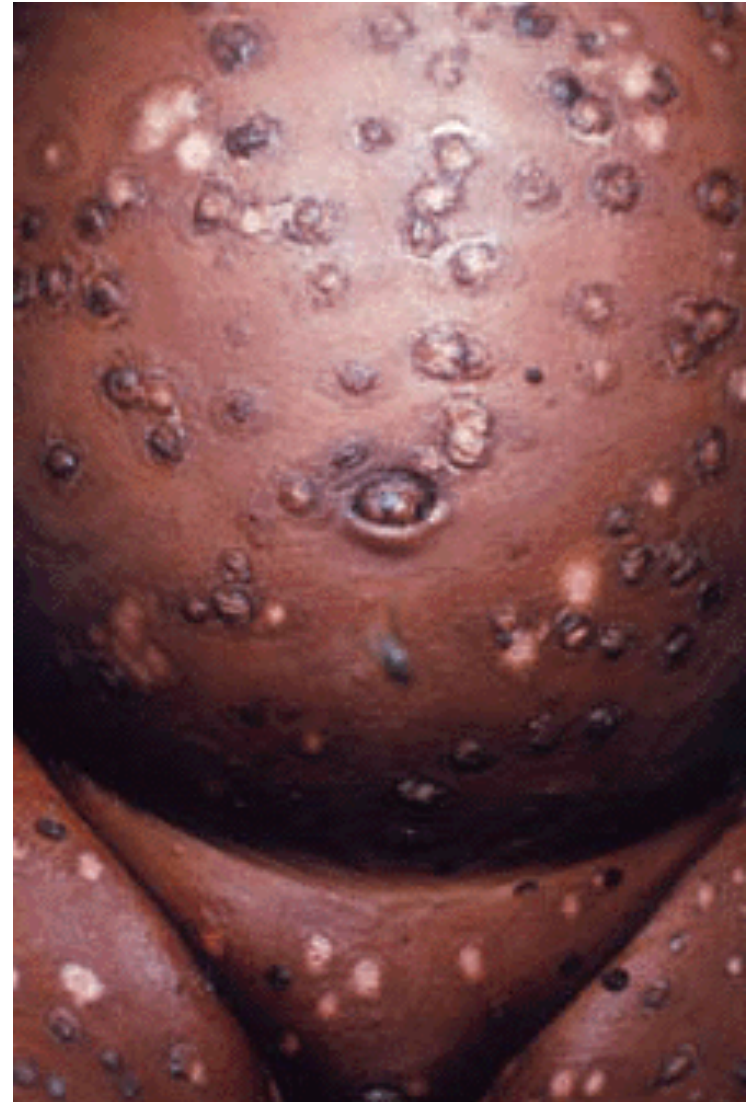On day 7, the rash is definitely pustular. Note that the pocks, although varying somewhat in size, all resemble each other in appearance. The rash is now so characteristic that there should be no mistake in diagnosis.



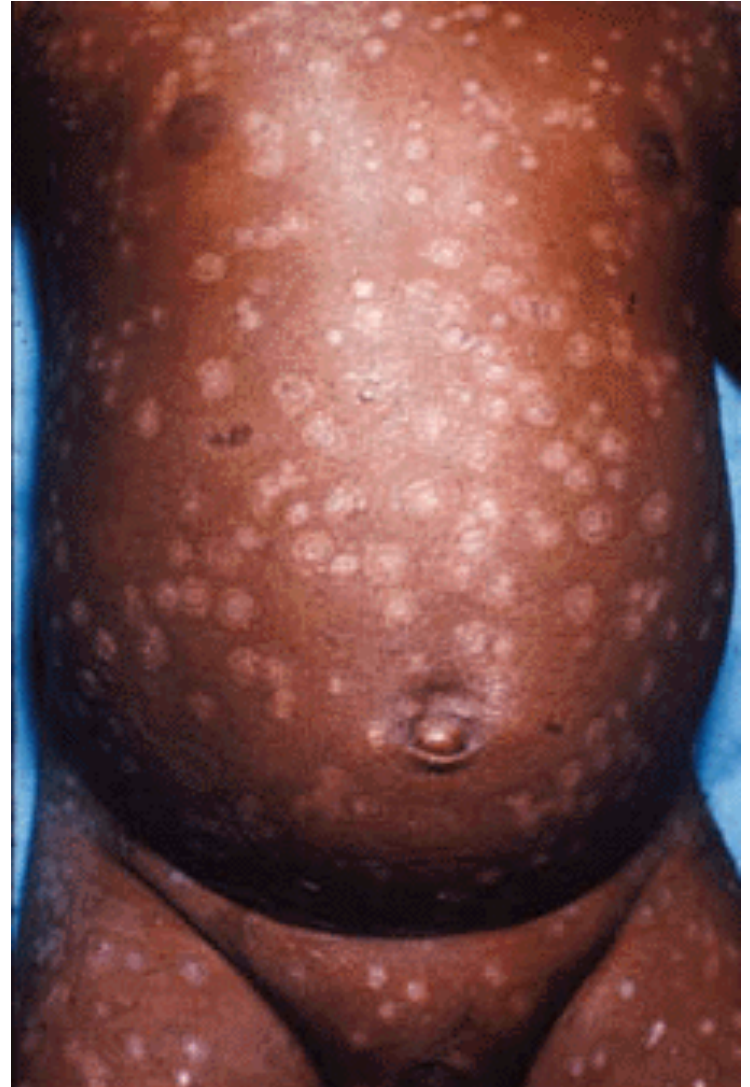During days 8 and 9, the pustules increase somewhat in size. They are firm to the touch and deeply embedded in the skin.




Gradually the pustules dry up and dark scabs form. The scabs begin to appear between 10 and 14 days after the rash first develops. The scabs contain live smallpox virus. Until all scabs have fallen off, the patient may infect others.



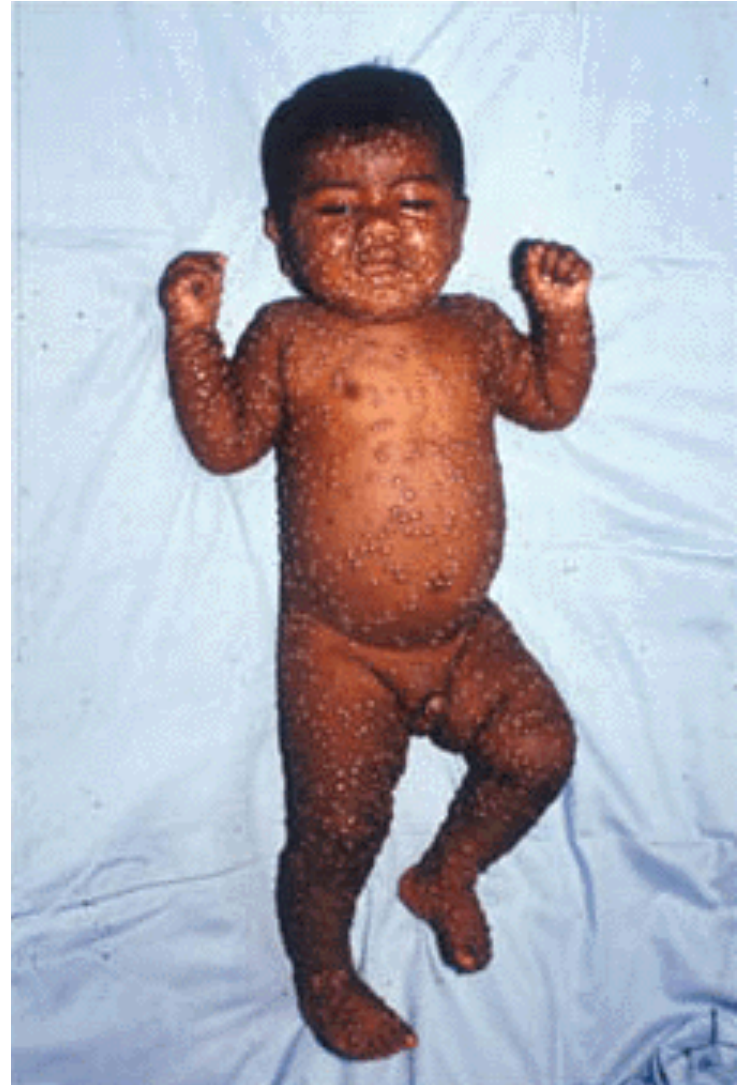By day 20, the scabs have come off and light-coloured or depigmented areas are observed. Over a period of many weeks the skin gradually returns to its normal appearance. However, scars which last for life may remain on the face. Such scars are an indication of previous infection with smallpox.

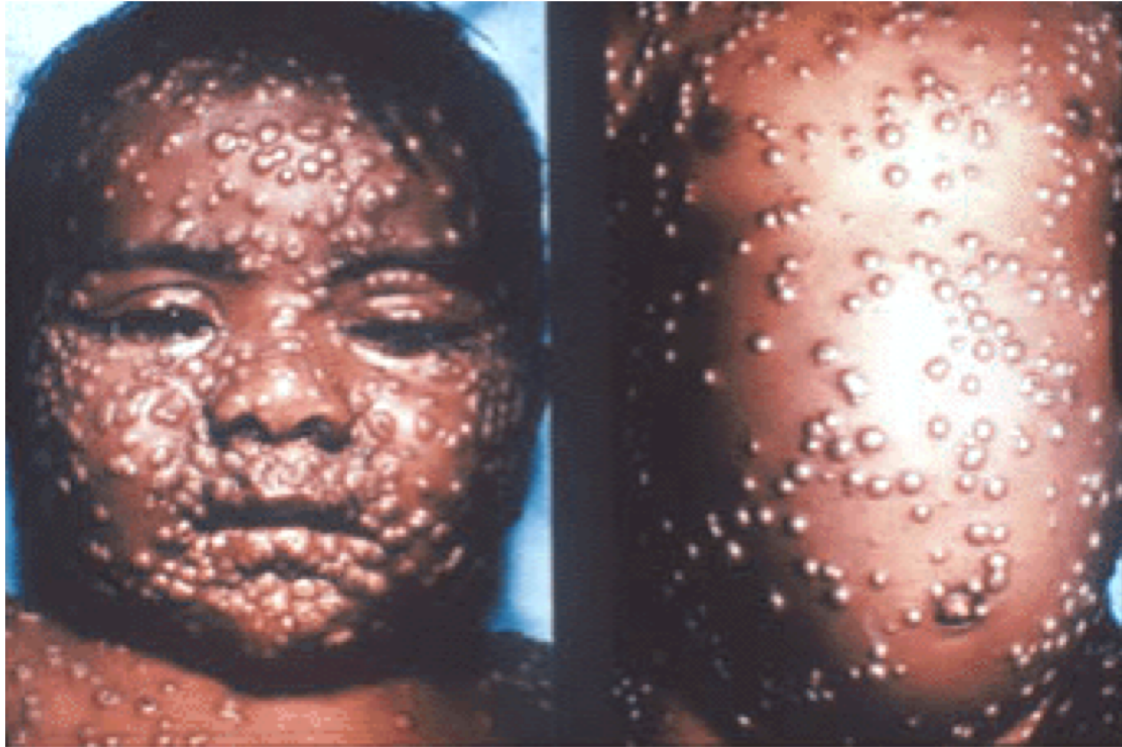



In this slide, the development of the rash is followed through consecutive stages. The numbers indicate the days after onset of rash on which the pictures were taken. Papules are seen on days 3 and 4; vesicles on day 5; pustules on days 7 and 9; and, finally, scabs on day 13.

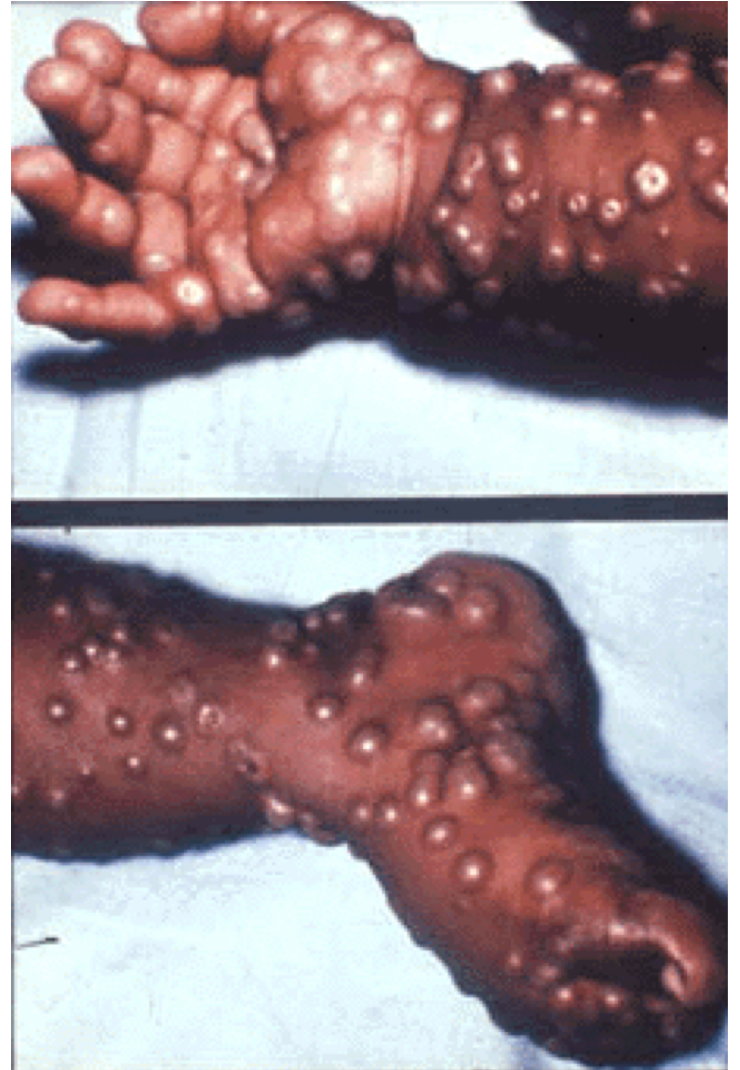The distribution of the smallpox rash is usually similar to that shown here. It is most dense on the face, arms and hands, legs and feet. The trunk has fewer pocks than the extremities.



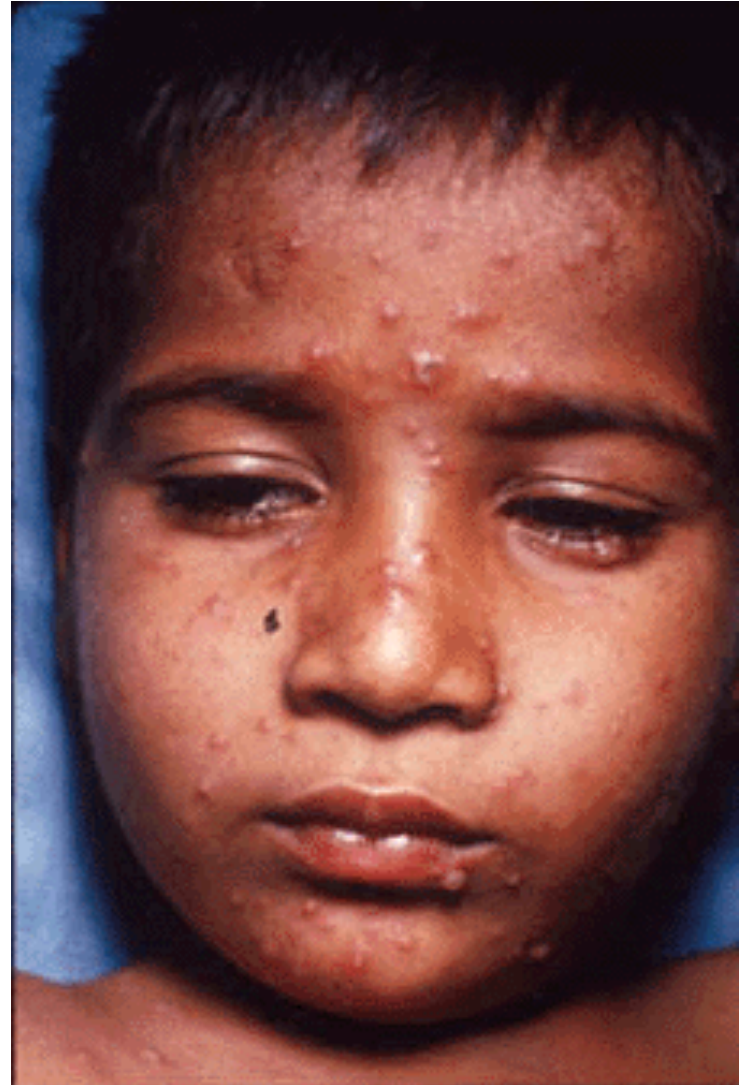

Note in this slide that the density of the rash is greater on the face than on the body.

Pocks are usually present on the palms of the hands and on the soles of the feet.



**This patient has chickenpox.
Chickenpox is the most
important disease likely to be
confused with smallpox. It is
caused by a different virus.**

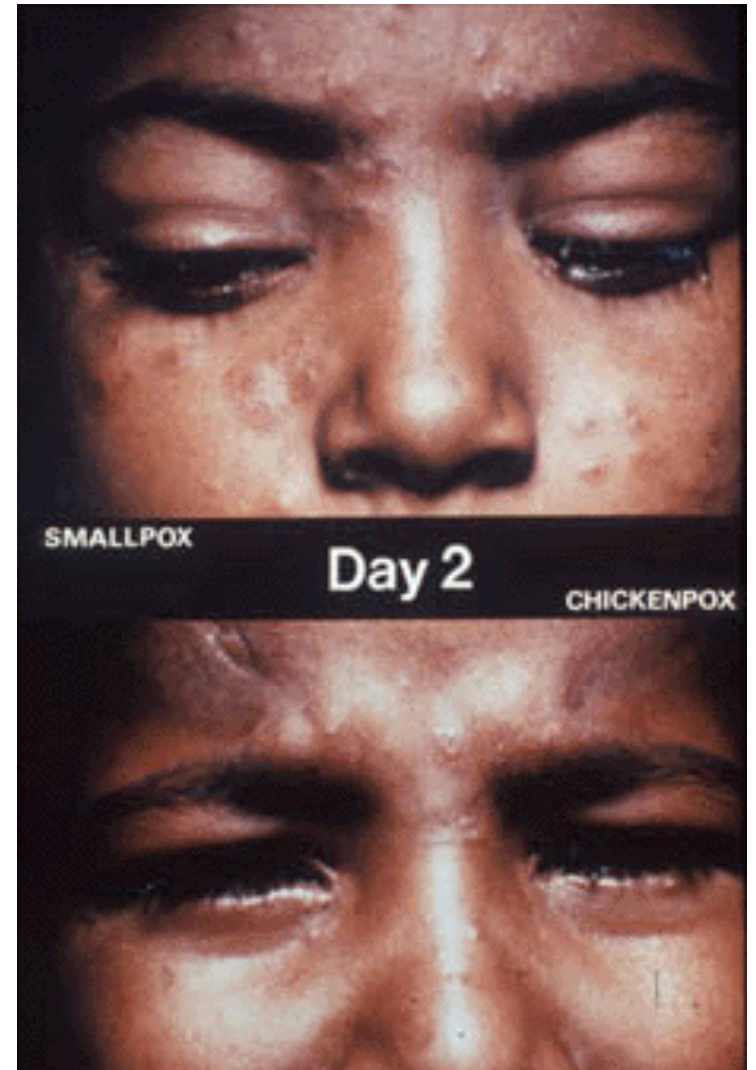


	SMALLPOX	CHICKENPOX
<i>FEVER</i>	2 to 4 days before the rash	At time of rash
<i>RASH</i>		
Appearance	Pocks at same stage	Pocks in several stages
Development	Slow	Rapid

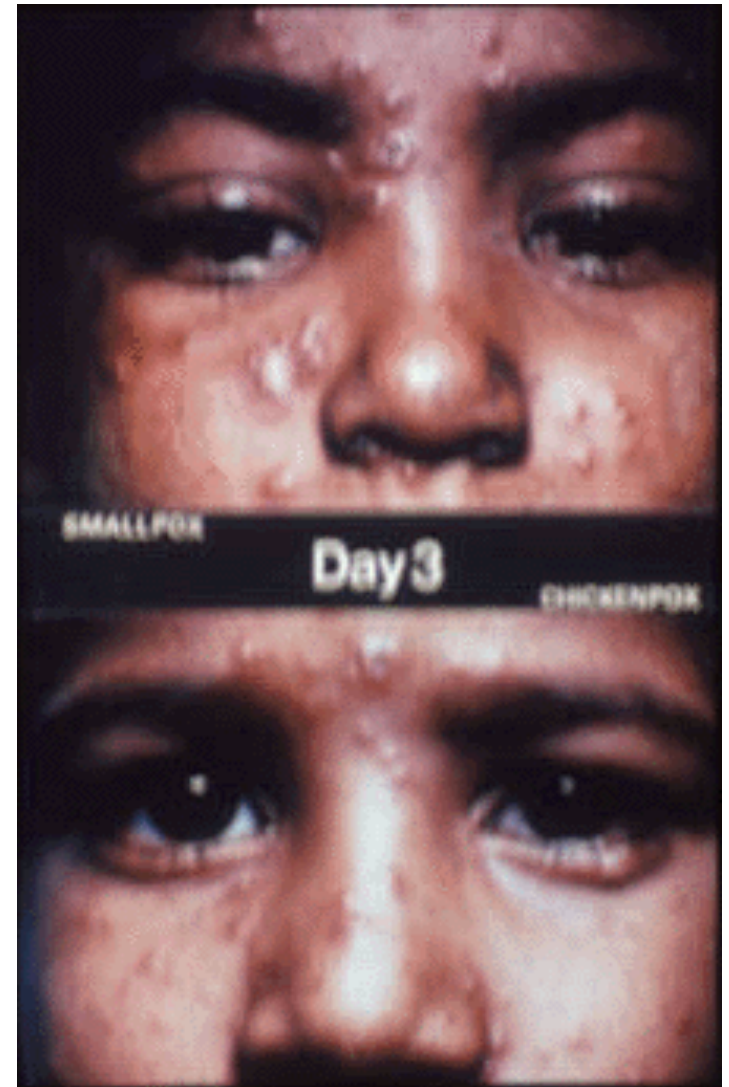
In smallpox, fever is present for 2 to 4 days before the rash begins, while with chickenpox, fever and rash develop at the same time.

All the pocks of the smallpox rash are in the same stage of development on any given part of the body and develop slowly. In chickenpox, the rash develops more rapidly, and vesicles, pustules, and scabs may be seen at the same time.

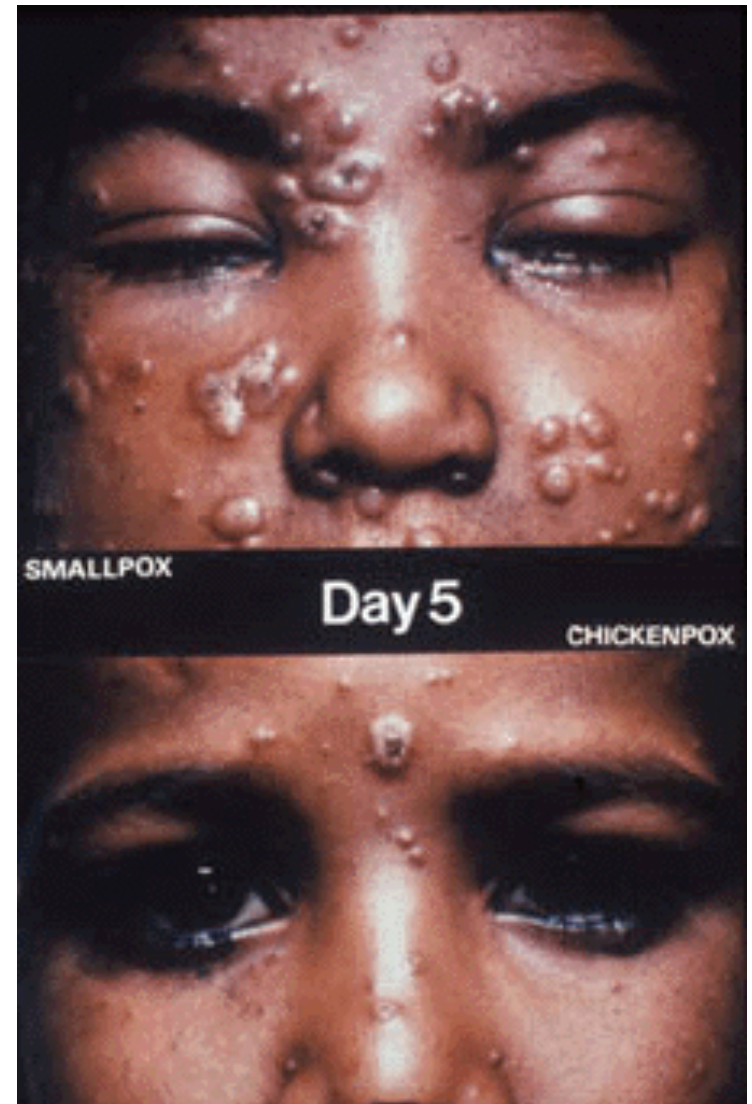During the first day or two of rash it may be impossible, from the rash alone, to differentiate smallpox from chickenpox.



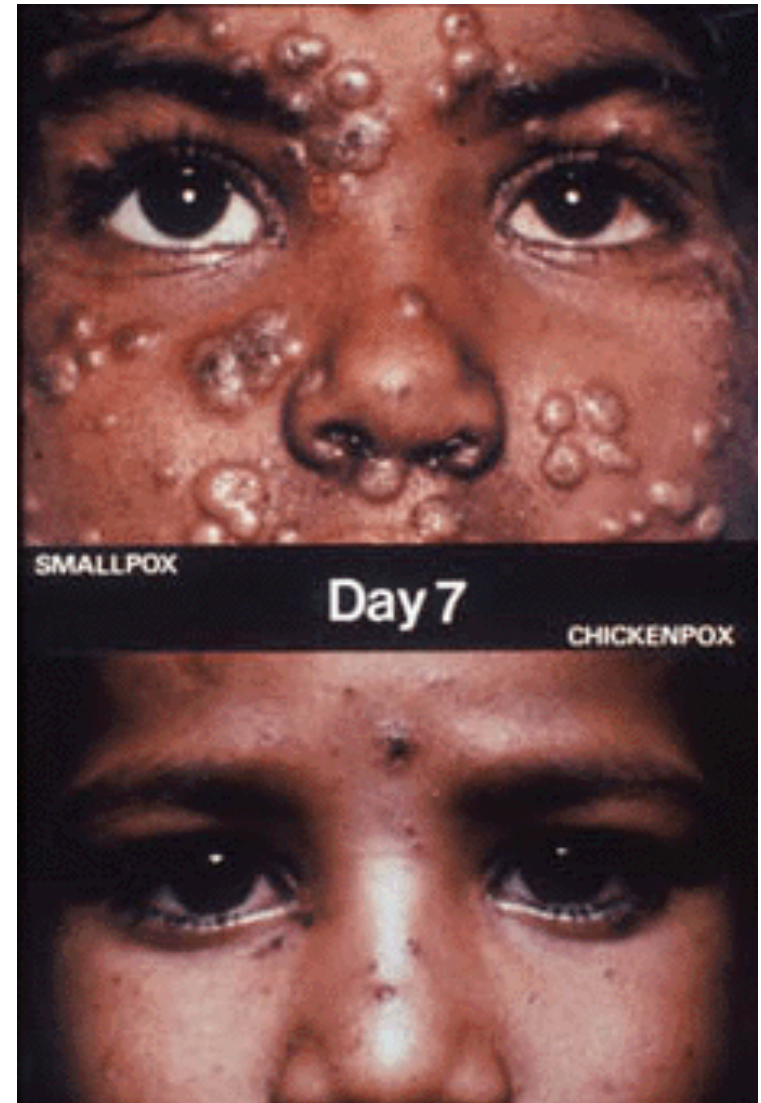
On day 3, the rash associated with each of the diseases continues to look very similar.



By day 5, however, it is perfectly clear that the patients have different diseases. The patient with chickenpox shows several different stages of rash. There are papules, vesicles and pustules present. However, all of the smallpox lesions are at the same stage of development. Most of the chickenpox lesions are small, between 1 and 5 mm, while the smallpox lesions are uniformly larger, between 5 and 10 mm. The smallpox pustules are firm and deeply embedded in the skin while the lesions of chickenpox are much more superficial.

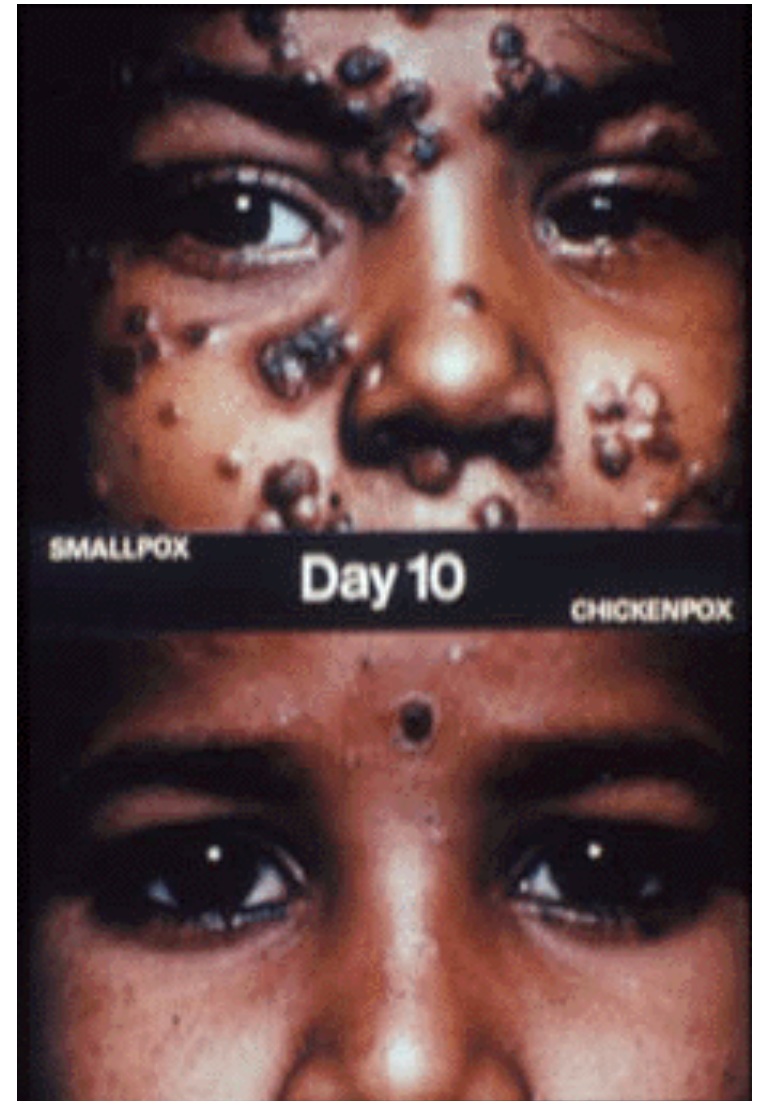


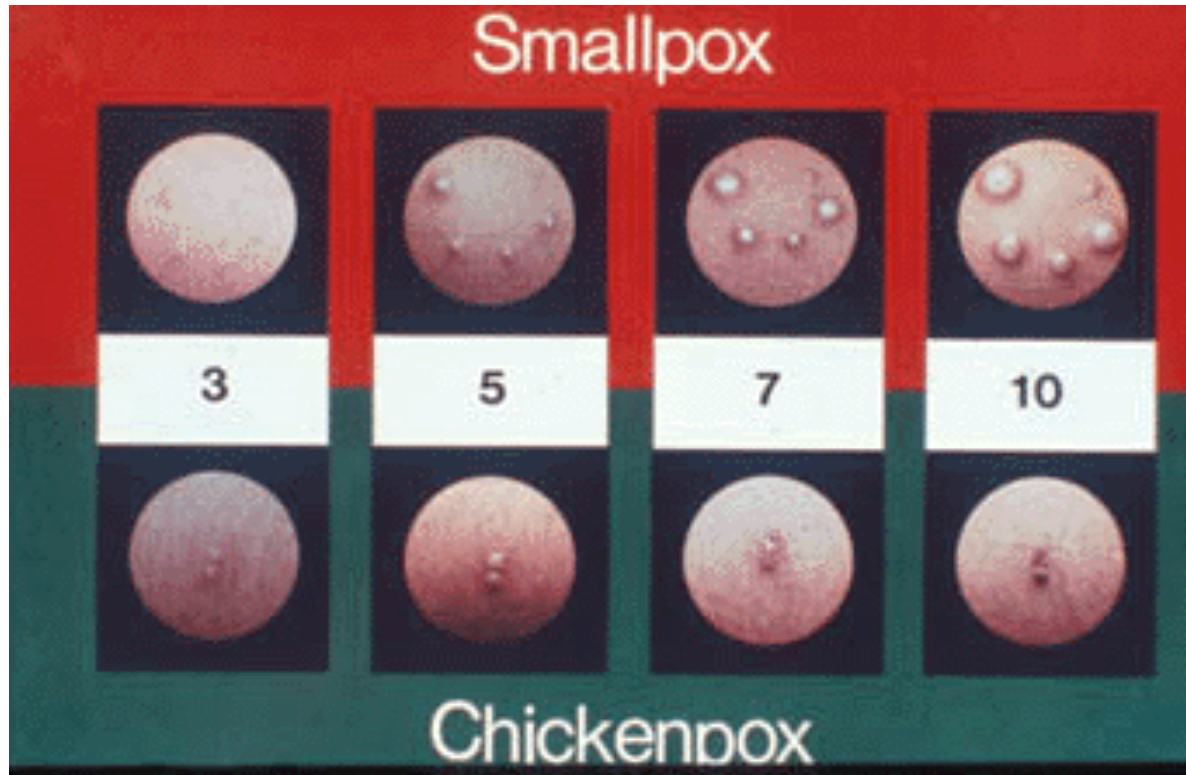
By day 7, most of the chickenpox lesions have already formed scabs and some scabs, in fact, have already separated. Scabs over the smallpox lesions have not yet formed.



On day 10 of the rash, most of the chickenpox scabs have fallen off, while the smallpox scabs are just beginning to form.

In chickenpox, the scabs may form as early as day 3 or 4 of rash and normally fall off by day 14.



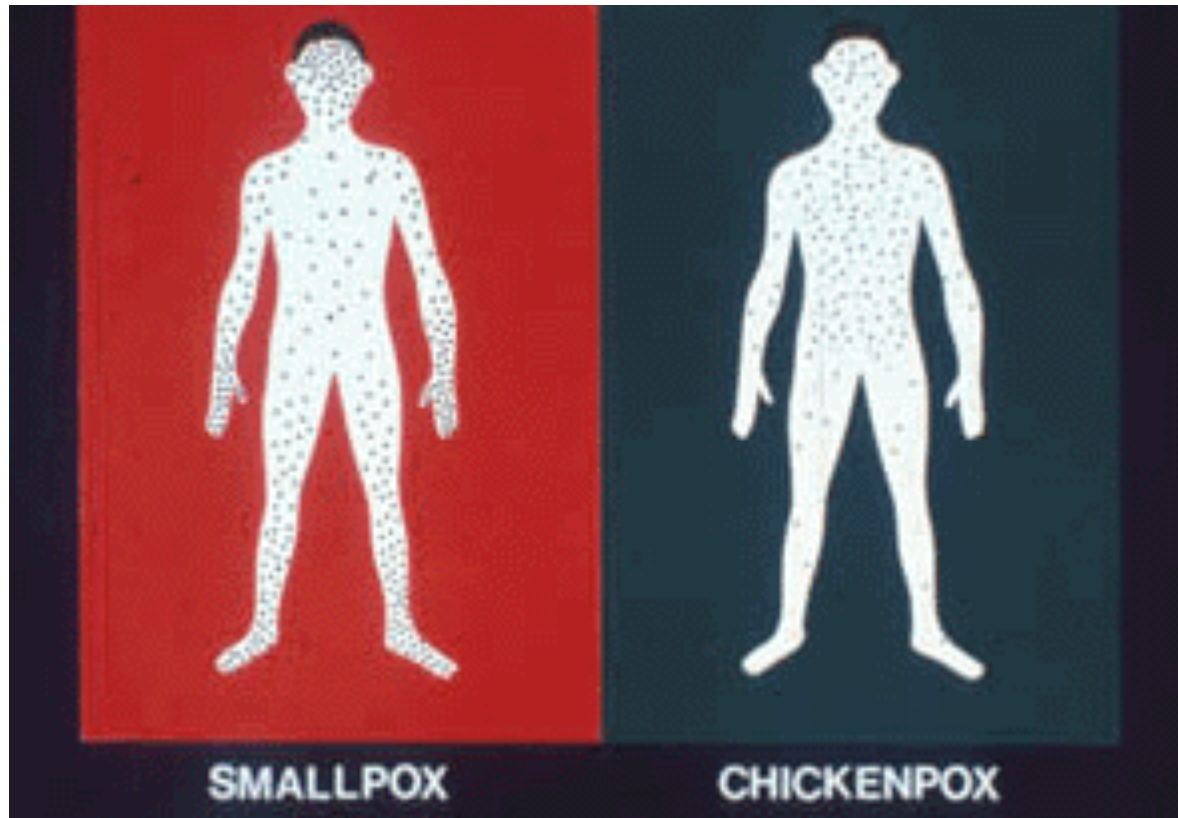


In this slide, pictures of the rash of chickenpox and smallpox are seen on each of four different days: day 3, day 5, day 7, and day 10. Note again that the chickenpox scabs have begun to form on day 7 while, in smallpox, no scabs are observed even on day 10.

	SMALLPOX	CHICKENPOX
<i>RASH</i>		
Distribution	More pock on arms and legs	More pocks on body
On palms and soles	Usually present	Usually absent

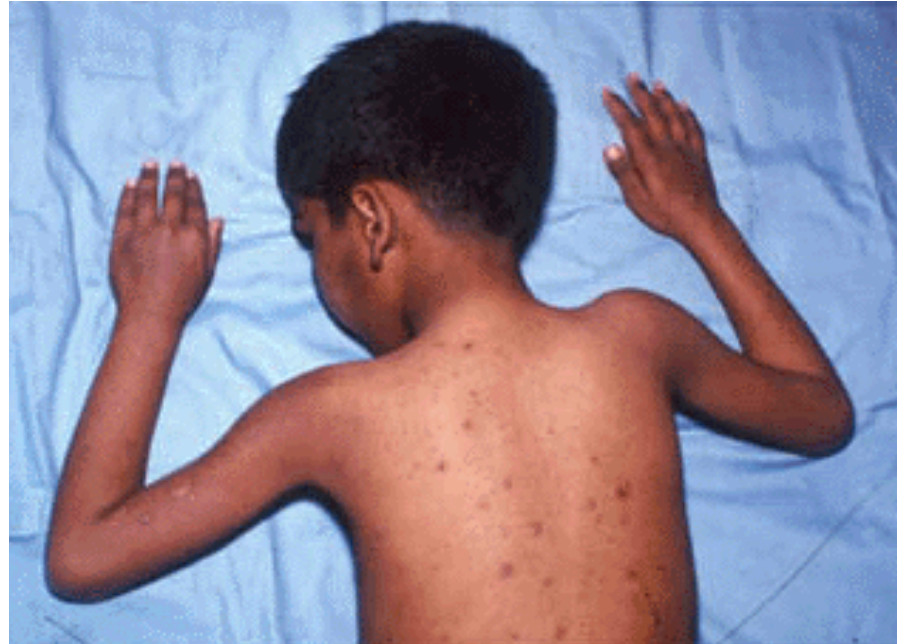The distribution of rash is also important in diagnosis.

In smallpox, more pocks usually occur on the arms and legs than on the body. In chickenpox, more pocks occur on the body. In smallpox, lesions are commonly found on the palms and soles. In chickenpox, however, there are very few or no lesions on the palms and soles.

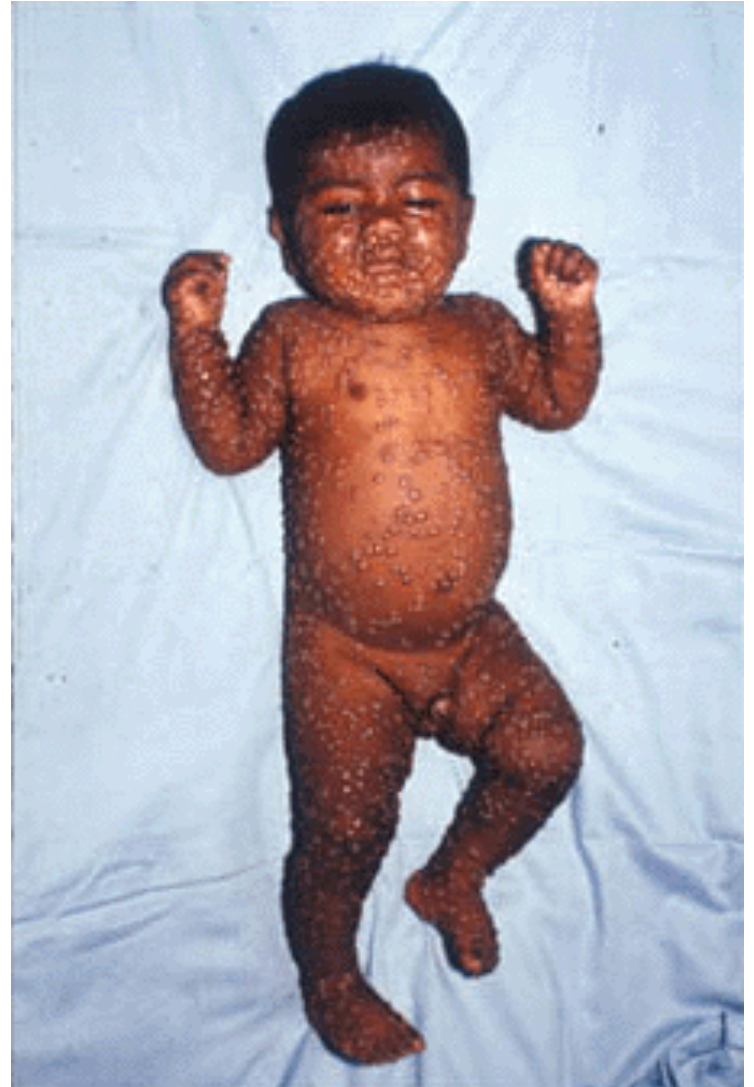

The relative density of rash on different parts of the body should be carefully observed. This diagram illustrates the differences that are usually seen.

In this picture of a patient with chickenpox, note that the patient has many pocks on his back but very few on his arms or hands.

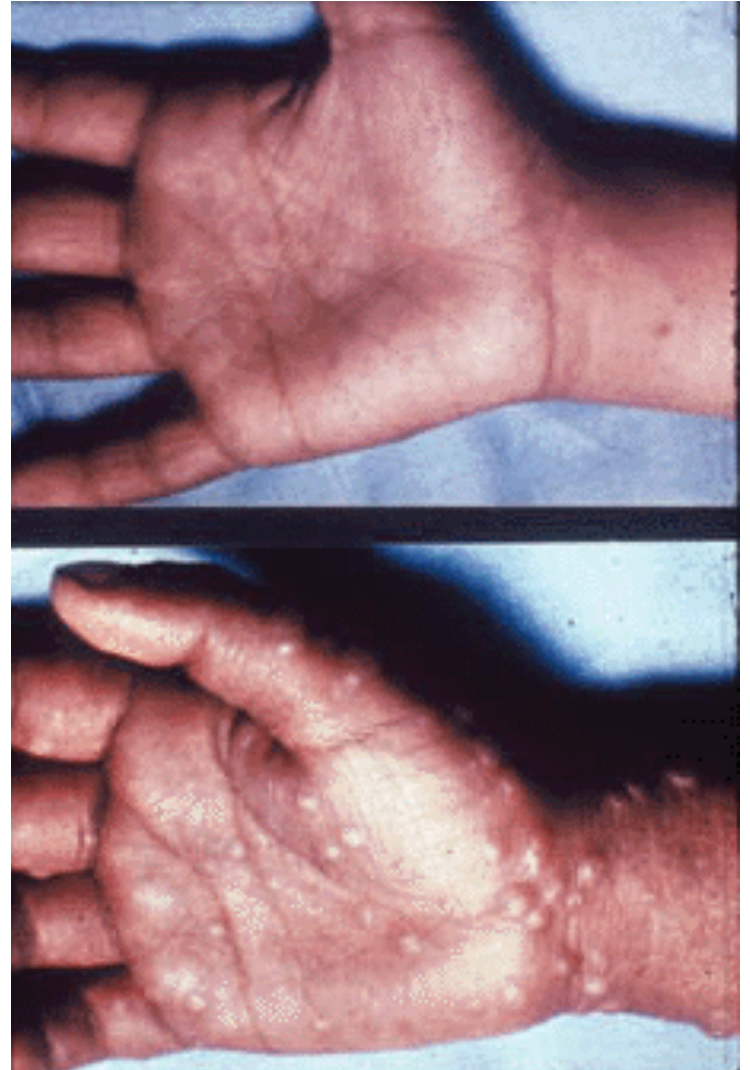

In smallpox, however, the pocks are more dense on the arms and legs than on the trunk.

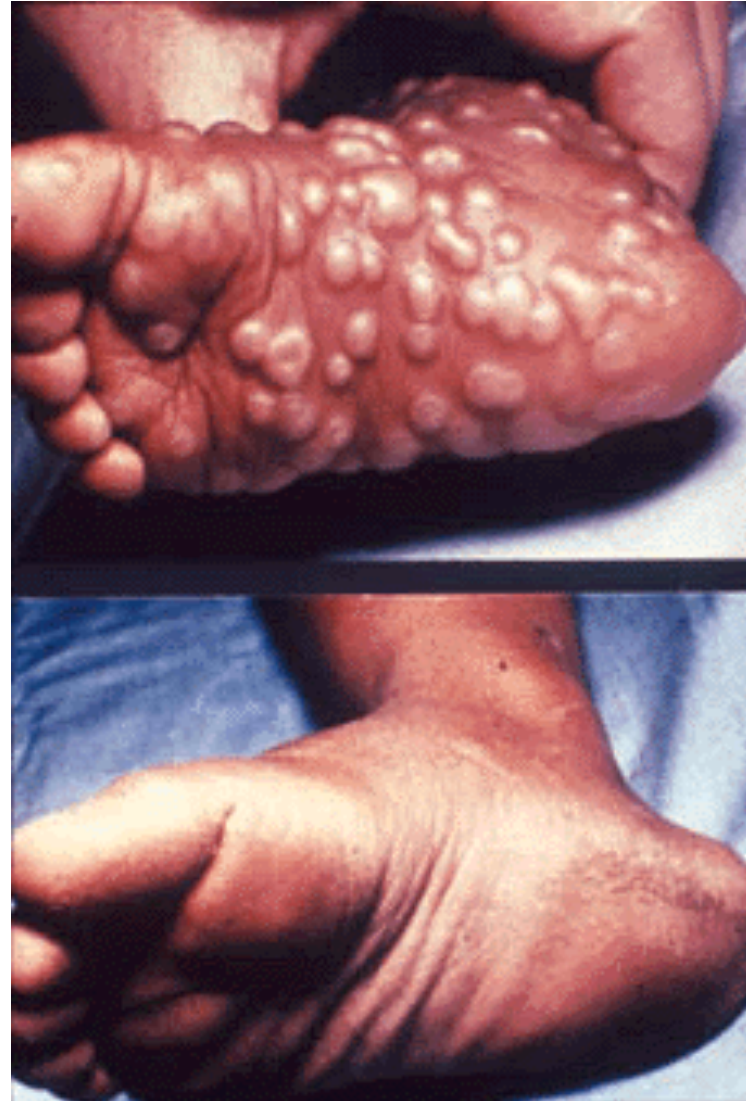

In smallpox (shown in the lower photograph), pocks are usually present on the palms of the hands.

In chickenpox there may be few or no lesions on the palms of the hands.



Similarly, on the soles of the feet, the smallpox patient may have many lesions but the chickenpox patient will have few or none.



	SMALLPOX	CHICKENPOX
<i>FEVER</i>	2–4 days before the rash	At time of rash
<i>RASH</i>		
Appearance	Pocks at same stage	Pocks in several stages
Development	Slow	Rapid
Distribution	More pocks on arms & legs	More pocks on body
On palms & soles	Usually present	Usually absent
<i>DEATH</i>	More than 10%	Very uncommon

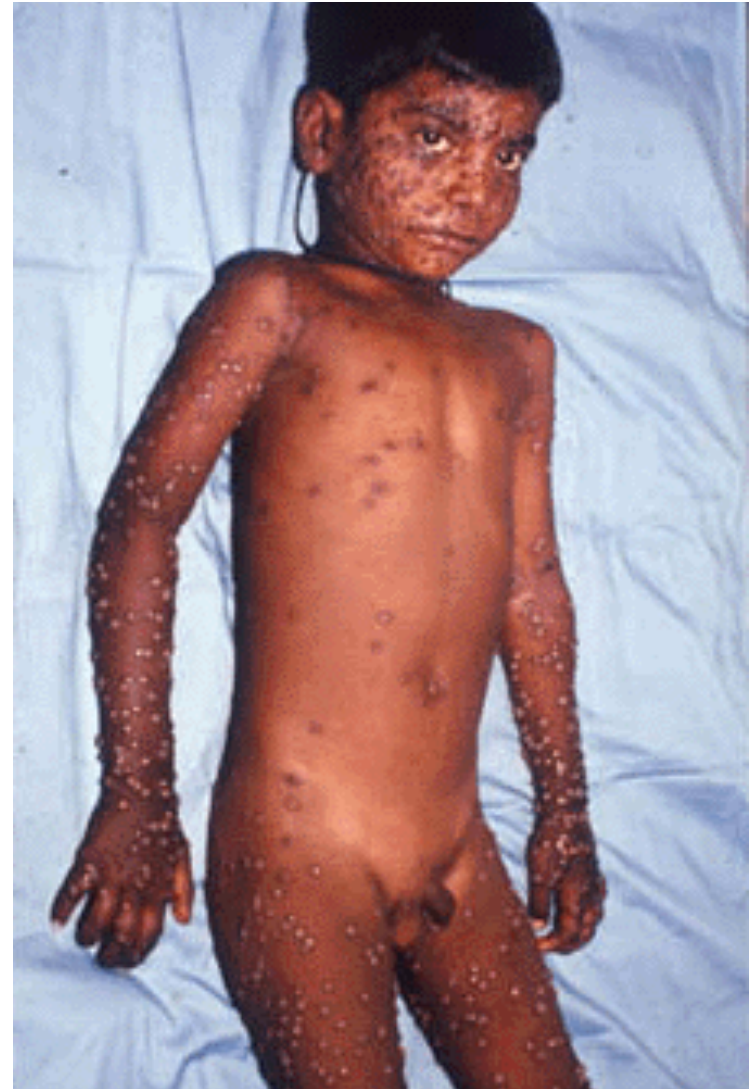Note again the particular points that help to differentiate smallpox from chickenpox:

- in smallpox, the fever precedes the rash by 2 to 4 days,
- the pocks on any part of the body are at the same stage of development, and they develop slowly,
- the pocks are more numerous on the arms and legs than on the body,
- the pocks are usually present on the palms and soles,
- death following smallpox is not uncommon, while in chickenpox death is very rare.

When death occurs in a patient in whom chickenpox has been diagnosed, smallpox should always be suspected.

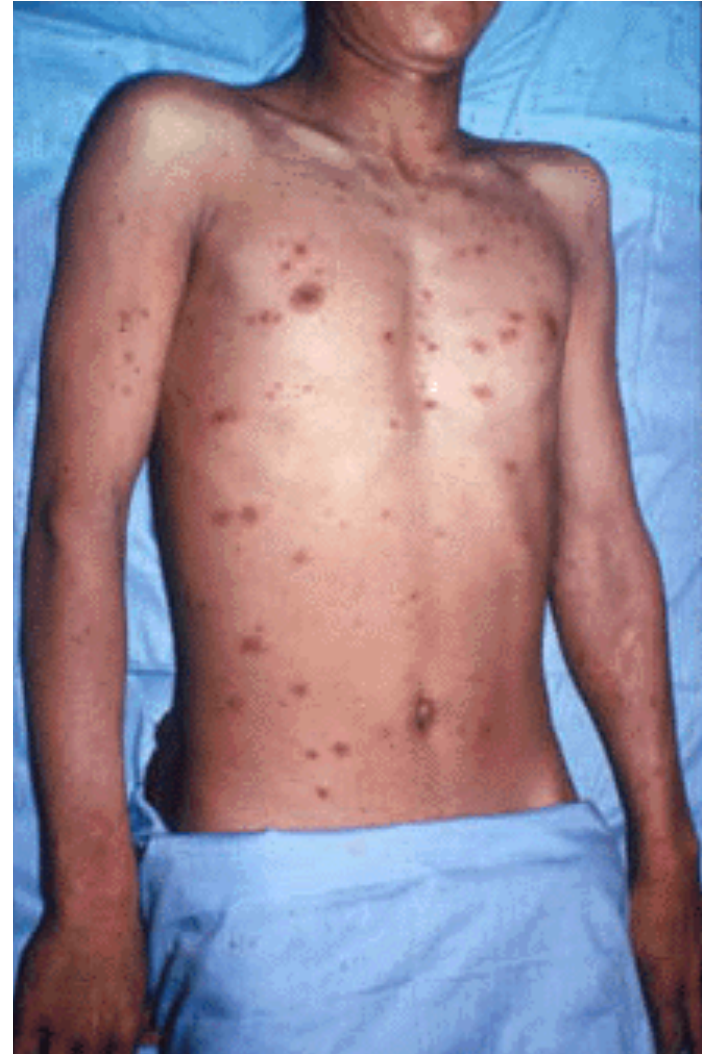This patient first developed a rash 10 days before this picture was taken. What is the diagnosis? Smallpox or chickenpox? After discussion, it is smallpox.

Note: (1) the pocks are at a similar stage of development in each area; (2) the distribution of the rash is characteristic for smallpox, with more pocks on the face and extremities than on the body; (3) although it is day 10 of rash, only a few scabs have formed.



This patient developed a rash three days before this picture was taken. What is the diagnosis? Smallpox or chickenpox? After discussion, it is chickenpox.

Note: (1) there are more pocks on the trunk than on the extremities, a distribution of rash that is characteristic for chickenpox; (2) different stages of the rash are seen—papules, vesicles, pustules and scabs; (3) pustules and scabs are present although it is only day 3 of rash; (4) most of the lesions are very small in size.

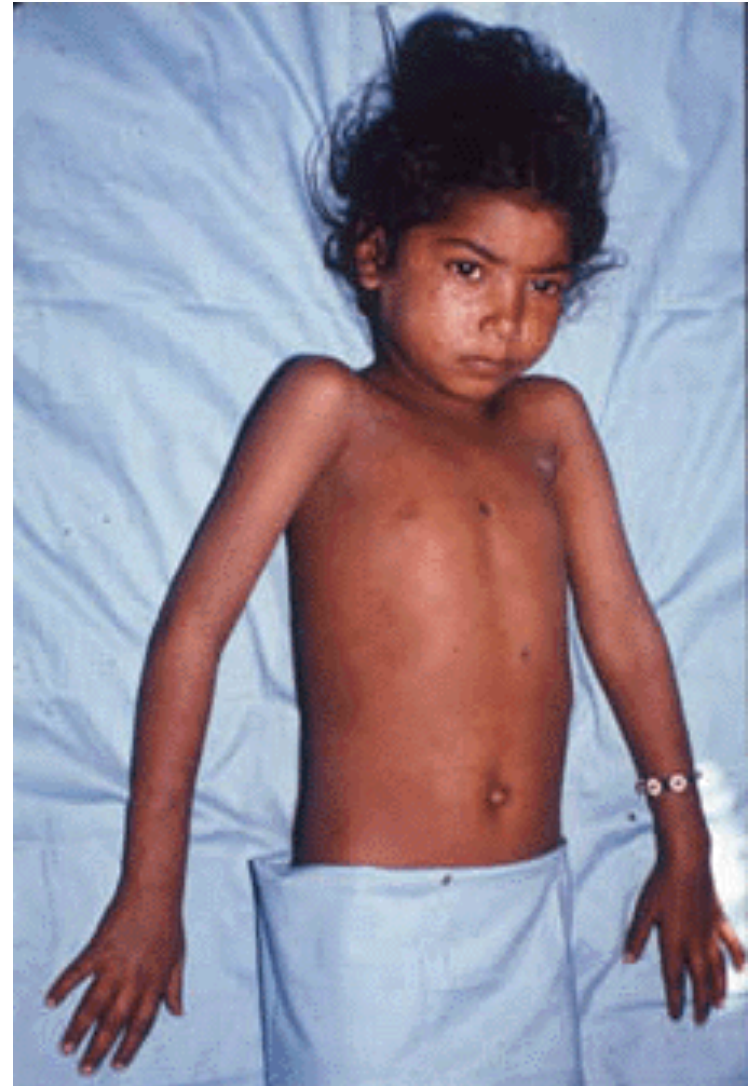

This patient first developed a rash the day before this picture was taken. What is the diagnosis? Smallpox or chickenpox?

After discussion: At this time, it is difficult to make a definite diagnosis simply from observation of the rash.

What other information might provide important clues to diagnosis?

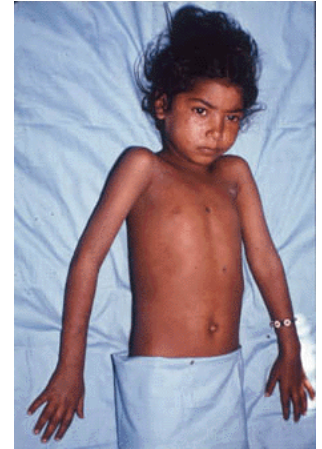After discussion: (1) If the patient had experienced 2 to 4 days of fever before onset of rash, this would suggest that she has smallpox. If fever developed at the time of rash, the diagnosis of chickenpox would be more likely. *(continued next page)*



(2) Information as to whether the patient had experienced either smallpox or chickenpox in the past would be helpful since second attacks of either disease are very rare.

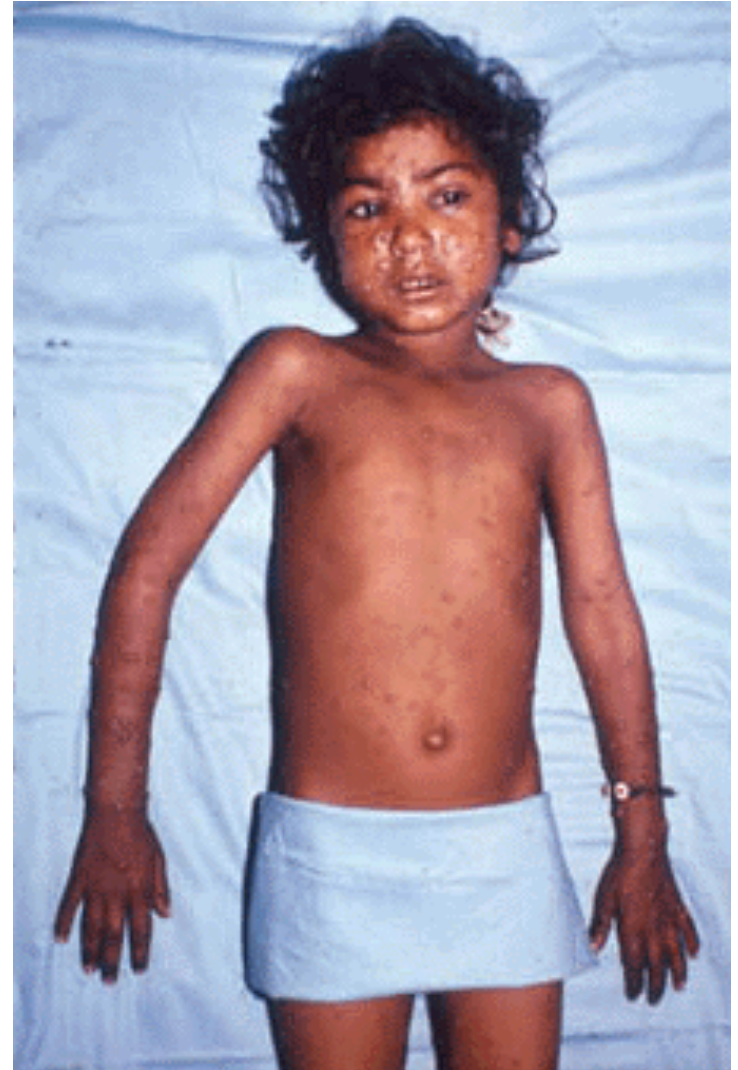(3) If mass vaccination of populations has been resumed and the patient has a vaccination scar, the diagnosis of chickenpox is more likely as few cases of smallpox are observed in previously vaccinated persons, especially those vaccinated within the preceding 5 to 10 days.

(4) A history of contact during the preceding 2 to 3 weeks with either a case of chickenpox or smallpox would provide valuable information. Note, however, that even with these clues to diagnosis, one may not be able to decide definitely one way or the other. The patient should be isolated and kept under observation. If the disease progresses as described for smallpox, samples should be collected for laboratory diagnosis.

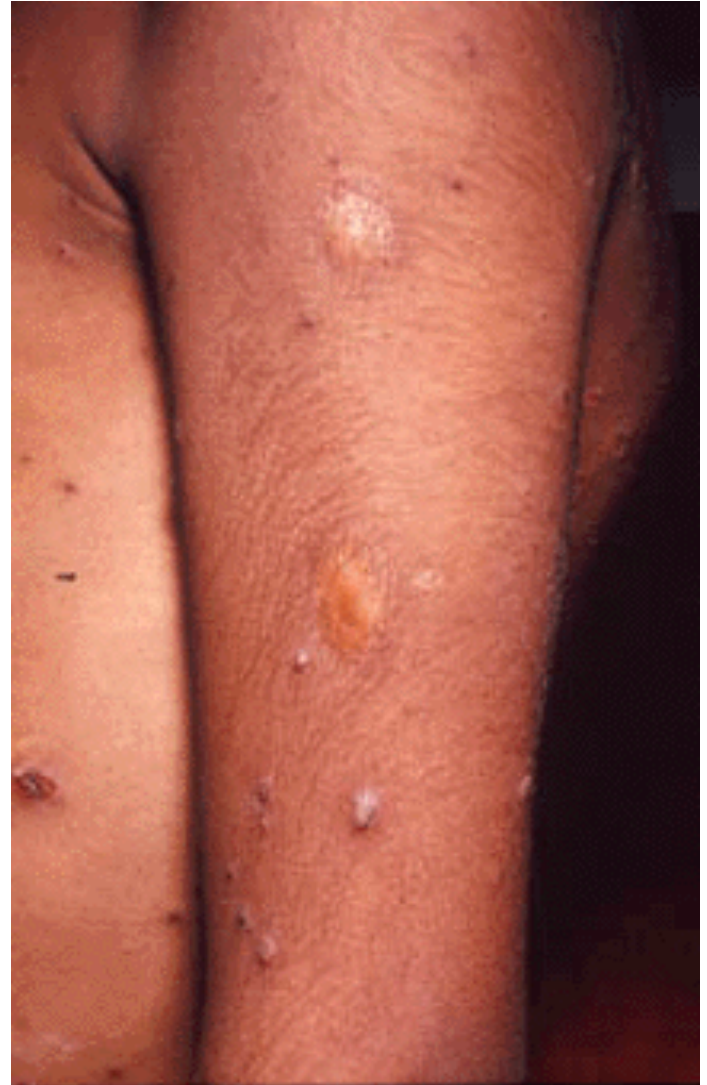

This is a picture of the same patient taken three days later. What is the diagnosis? Smallpox or chickenpox? After discussion: It is now perfectly apparent that the child has smallpox.

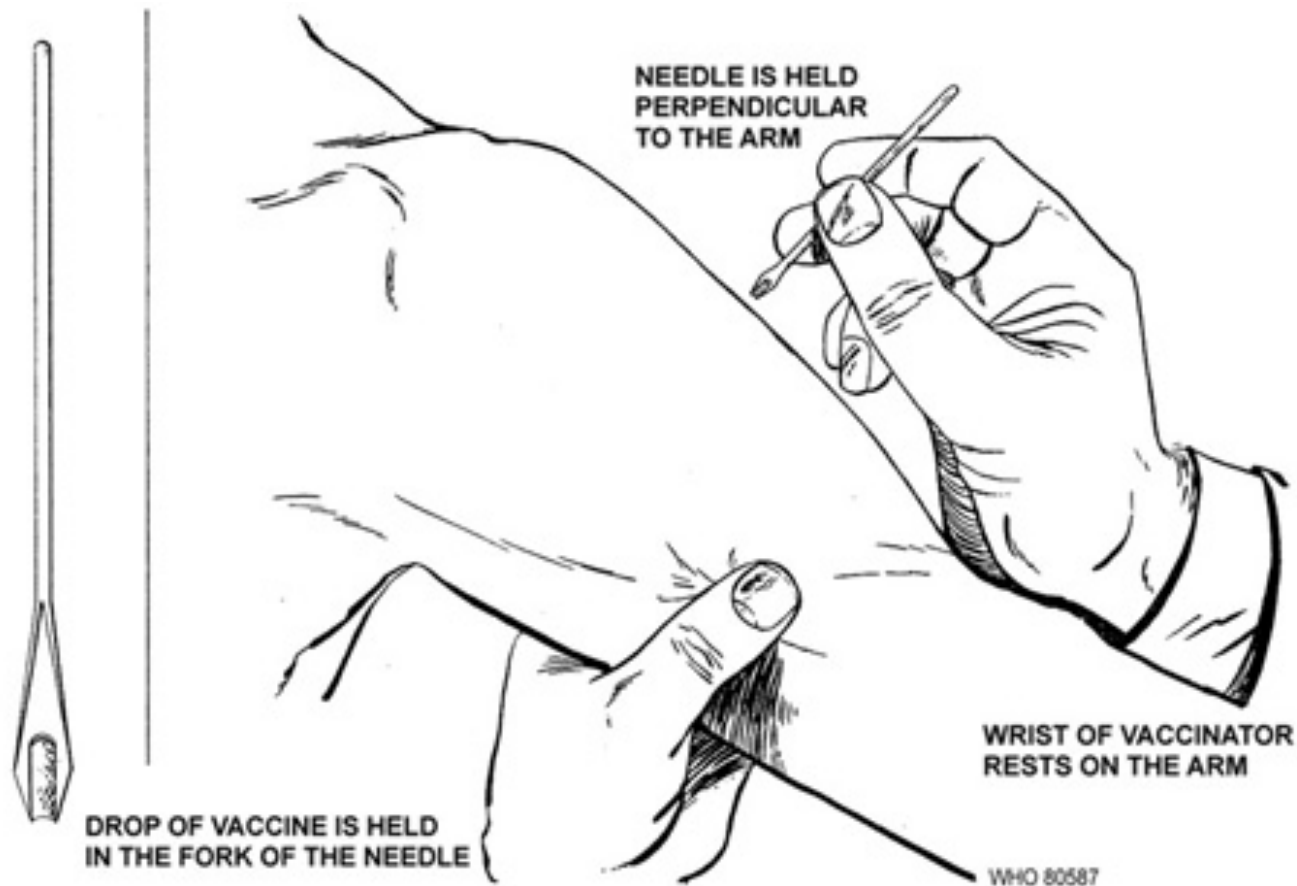
Note that the pocks are all in the same stage of development and now, on day 5 of rash, characteristic pustules are present. The distribution of the rash is also typical.



This patient first developed a rash six days before this picture was taken. What is the diagnosis? Smallpox or chickenpox? After discussion: It is chickenpox. Note: (1) different stages of the rash are seen; (2) scabs are already present although it is only day 6 of rash; (3) smallpox vaccination scars are seen, thus making it less likely that the patient has smallpox.



Multipuncture vaccination by bifurcated needle



Recognition card (recto/verso)

